Dr.Harinikrishna
Aravind eye hospital ,
Madurai

KERATOCONUS

Keratoconus is a non-inflammatory corneal ectasia characterised by progressive corneal thinning and apical protusion.

- Most common in adolescent age group.
- Prevalence in men and women found to be equal.
- Asians have four fold higher incidence.
- Autosomal dominant inheritance is very common.

Etiology :-

- Sporadic
- Hereditary
- Eye rubbing

↓

micro trauma

↓

epithelial injury

↓

release of inflammatory mediators

↓

apoptosis of keratocytes and corneal thinning.

- Contact lens wear - causes micro trauma
- Atopy (causing rubbing of eyes)

Association with Keratoconus

Systemic

- Downs syndrome
- Turners syndrome
- Atopic dermatitis
- Bardet - Biedl syndrome
- Ehler Danlos syndrome

Ocular

- VKC
- Lebers congenital amaurosis
- Retinitis pigmentosa

Pathophysiology :-

↑ cathepsins, gelatinases and other degradative enzymes

↓

collagen loss, interlamellar and interfibrillar slippage of

collagen within stroma

↓

loss of cohesion between collagenous and non collagenous matrix

Histology :-

- severe corneal stromal thinning and focal deficits in epithelium and Bowmans layer.
- Endothelium is usually normal.
- Deposition of iron in basal epithelial cells. } Fleischer's ring
- Descemet membrane rupture can cause fluid influx into stroma causing HYDROPS.

Clinical features :-

- Patients are in late teens or early twenties.
- Usually bilateral.

Symptoms :-

- Defective vision
- Frequent change of glasses.
- Monocular polyopia or ghosting.

Signs :-

1. **Munson's sign :-**

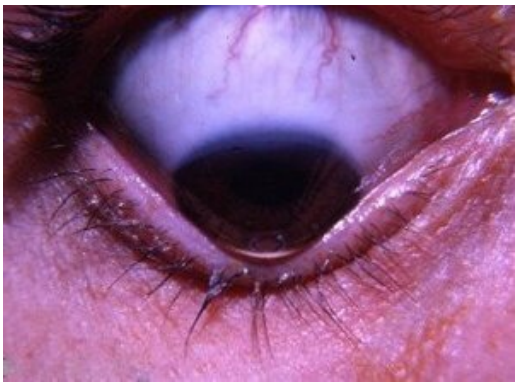

Indentation of lower lid caused by the protruding apex of keratoconus.

2. Rizutti sign :-

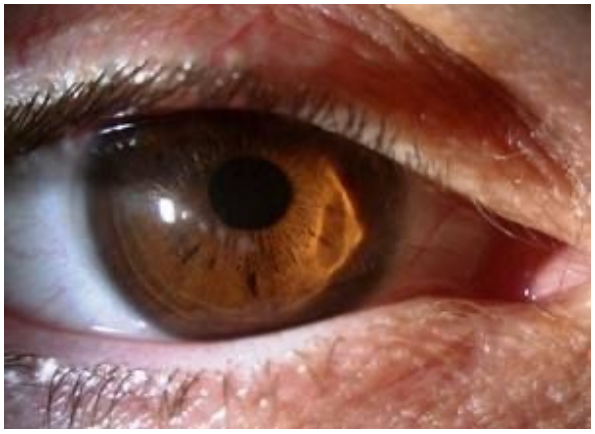

Light reflex projected from temporal side will be displaced beyond nasal limbal sulcus.

SLIT LAMP SIGNS :-

1. Vogt's striae :-

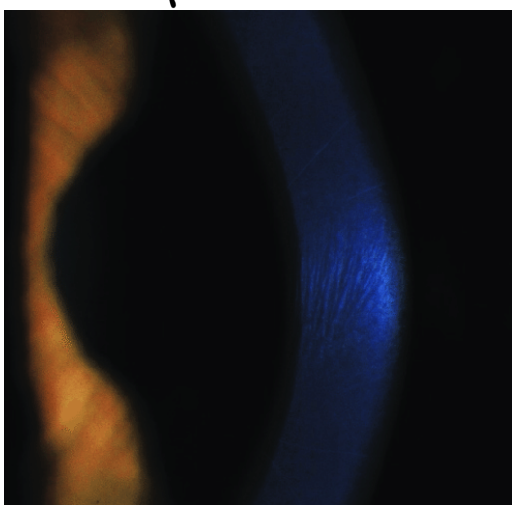

Fine stress lines in deep stroma. Earliest slit lamp finding.

2. Fleischer ring :-

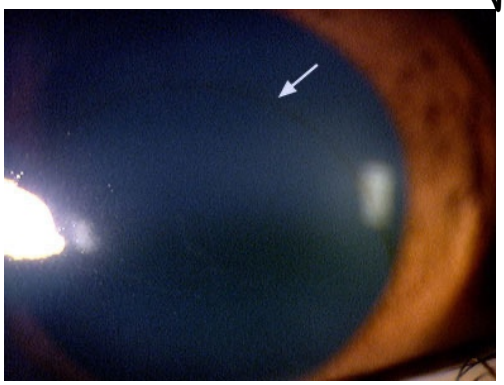

Deposition of iron in basal epithelial cells in a ring shape at base of conical protrusion

3. <u>Prominent corneal nerves</u> :-

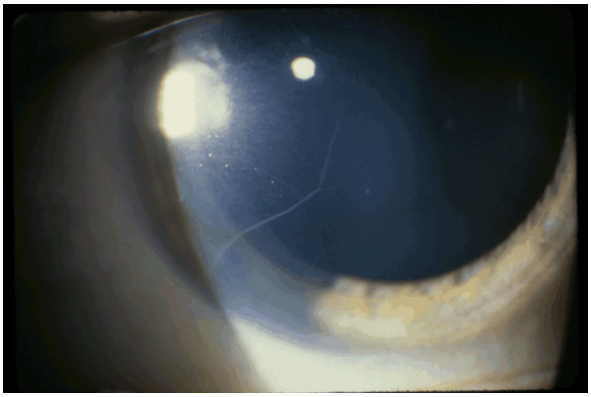

Nerves are seen more easily due to change in corneal density

4. <u>Corneal apical scarring</u> :-

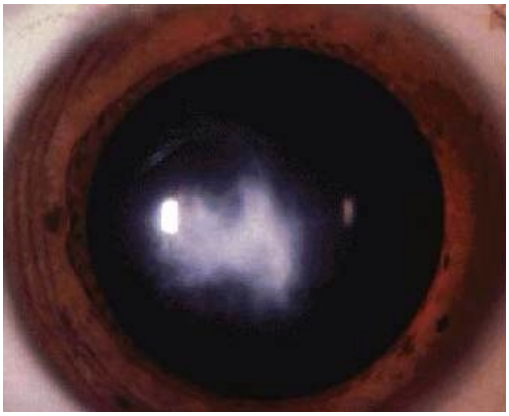

Scaring occurs at the apex of cone and develops into nebular scaring.

5. <u>Hydrops</u> :-

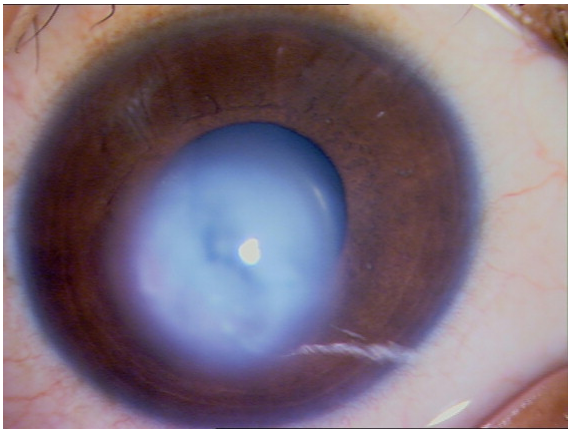

Rupture in descemet membrane causes influx of aqueous into stroma.

Retroillumination signs :-

1. Scissoring reflex :-

Reflex appears to spin or swirl around a point corresponding to apex of cone on retinoscopy.

Central part of cornea → hyperopic → with movement.

Peripheral part of cornea → myopic → Against movement

2. Oil droplet sign :-

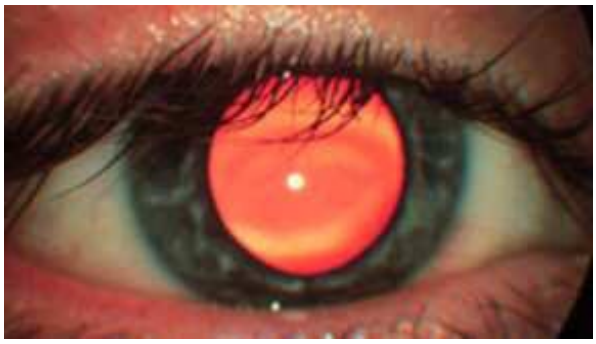

Due to complete internal reflection of light.

Keratoscopy signs :-

- Egg shaped mires.
- Localised increase of power in inferotemporal / inferior cornea.
- Inferior superior dioptric asymmetry
- skewing of radial axes above and below the horizontal meridian with asymmetric bow-tie pattern. (SRAX).

Egg shaped mires

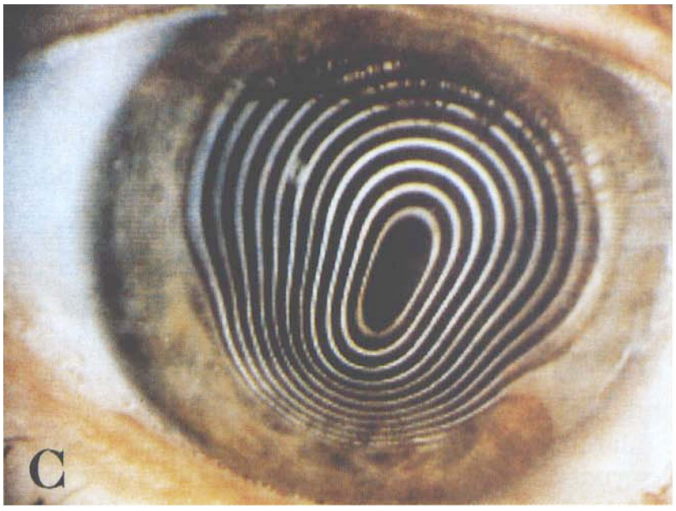

SRAX

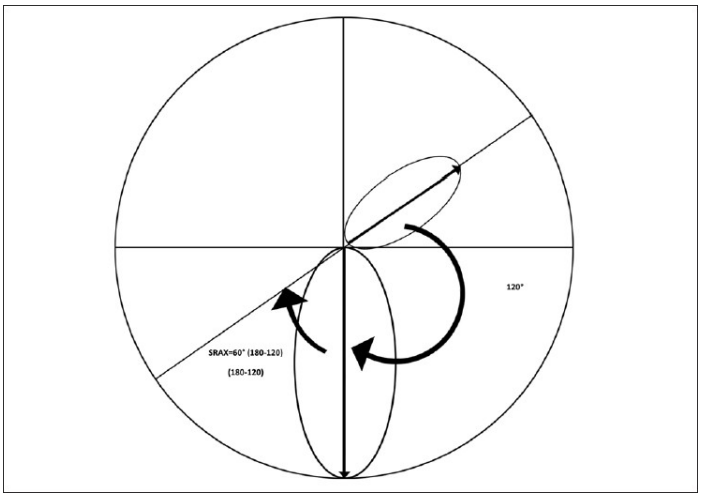

Diagnosis

Based on severity of curvature

- Mild : <45 D in both meridians
- Moderate : 45-52 D in both meridians
- Severe : >52 D in both meridians
- Advanced : >62 D in both meridians

Based on shape of cone

- Nipple small diameter (5 mm); round shape; easiest to fit with contact lenses
- Oval large diameter (>5 mm); often displaced inferiorly; more difficult to fit with lenses, most common by topography
- Globus largest diameter (>6 mm); 75% of cornea affected; most difficult to fit with lenses

Nipple cone

oval cone

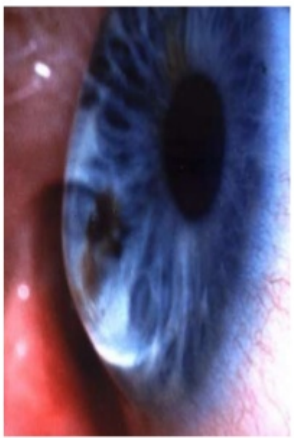

globus

RABINOWITZ CRITERIA (1995) FOR DIAGNOSIS OF KERATOCONUS :

- central corneal power > 47.2 D
- inferior minus superior (I-S value) asymmetry >1.2 D
- Sim K astigmatism > 1.5 D, and (steep stimulated k)
- SRAX > 21^0 (skewed radial axes (SRAX) of astigmatism)

- KISA % - K × I-S asymmetry × AST (Degree of astigmatism) × SRAX × 100.

> 100 % - suggestive of keratoconus.

60 - 100 % - keratoconus suspects.

- Orbscan corneal topography II is a combination of placido disc & scanning optical slit design. It

analyses 240 points per slit and calculates the corneal thickness & posterior surface of entire cornea.

Most important parameters } - Anterior and posterior corneal elevation.

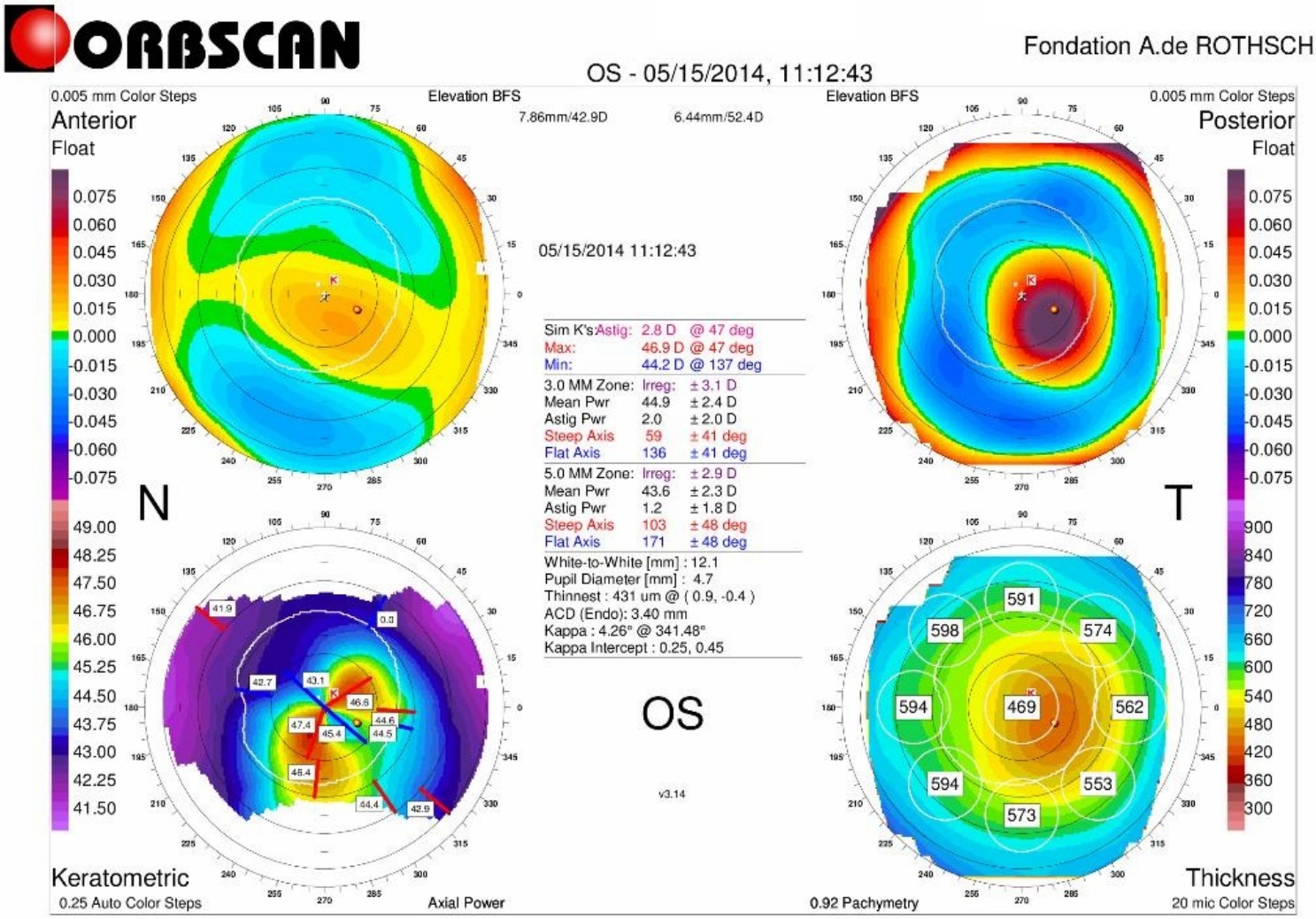

Treatment :

Five point management

1. Diagnosis and environmental modifications.
2. Spectacles | contact lens.
3. Collagen cross linking (C3R).
4. C3R plus | ICRS.
5. Surgery - DALK / penetrating keratoplasty.

Spectacles :-

- Can be used in early stages.
- Does not affect | prevent the progression of the disease.

CONTACT LENS :-

→ Rigid gas permeable (RGP) lens are usually used acc. to the keratometry values.

Three point touch flourescin pattern use for selection of back optic zone radius.

- slight central touch showing thinning of flourescin.
- slight touch mid peripherally at 3' o clock and 9' o clock along horizontal meridian.

- Four zones are created:
  - Slight apical touch
  - Paracentral clearance
  - Mid-peripheral bearing
  - Peripheral clearance



→ Soper lens - bicurve design with steep central curve & flatter peripheral curve.

→ Hybrid lens → RGP optic zone surrounded by a soft skirt.

→ Piggy back lens → RGP lens worn over a soft lens.

→ Rose-K lens → lens with computer generated peripheral

curves based on pre-collected data.

→ Scleral lens → large contact lenses used in cases of advanced keratoconus.

ICRS - Intrastromal corneal ring segments.

INTACS is the most commonly used.

- They are placed at a depth of 2/3 eds corneal thickness.

- Used in contact lens intolerant patients with early keratoconus and minimal stromal scarring.

- Thickness of INTAS - 0.25 - 0.45 mm
  Inner diameter - 6.8 mm
  Outer diameter - 8.1 mm
  Arc length - 150°

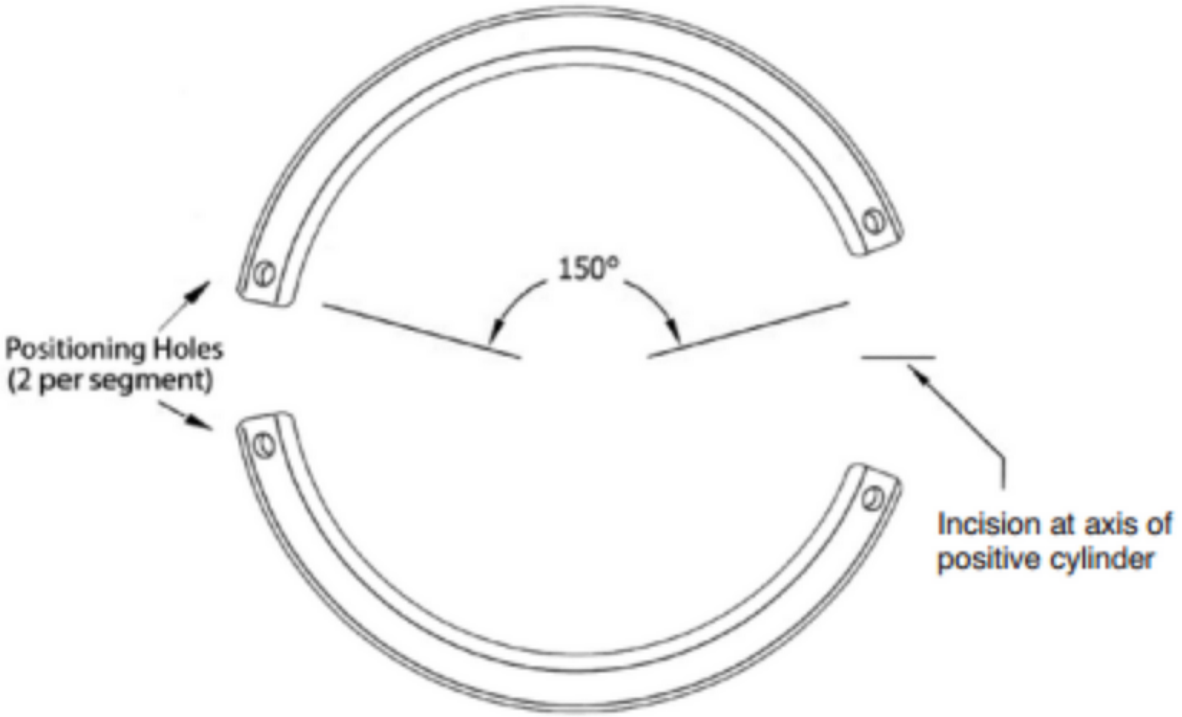

C3R - collagen cross linking with riboflavin

C3R causes increased collagen cross-linking within the corneal

stroma to enhance its mechanical strength.

Riboflavin acts as a photosensitizer and when combined with UV-A radiation increases the formation of intrafibrillar and interfibrillar covalent bonds.

- Can be done when keratometry value < 48 D, corneal thickness } ≥ 400 µm

Dresden protocol

- Central 8-10 mm epithelium removed.
- 0.1% riboflavin & 20% dextran applied 30 mins before & at 5 min interval during 30 mins exposure to 370 nm UVA (3 mW/cm²).

Hypoosmolar C3R } - when corneal thickness is borderline to swell tissue.

Complications :-

→ infection
→ sterile infiltrates.
→ delayed reepithelization
→ corneal edema and haze.

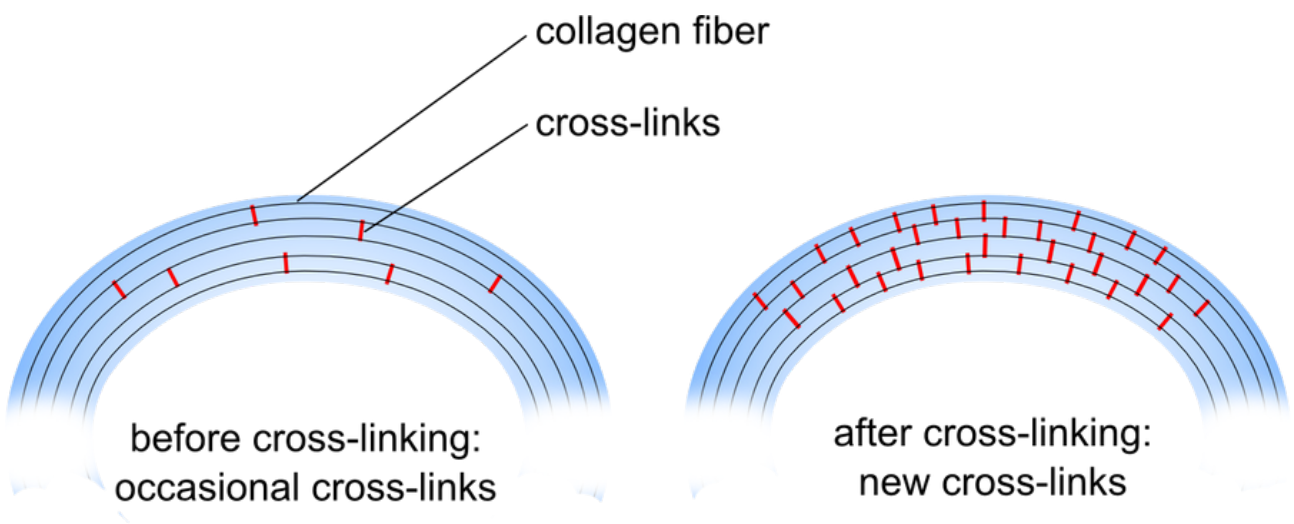

C3R plus

- C3R with topography guided photo refractive keratectomy

ATHENS PROTOCOL

Excimer LASER epithelial debridement (50 µ)

↓

topography guided excimer LASER stromal ablation

↓

accelerated C3R (10min) c̄

UVA radiation (10mW/cm²).

- C3R with ICRS can be done

- C3R along with phakic IOL can be done.

Accelerated C3R

Bunsen-Roscoe law of photo chemical reciprocity states that the same photochemical effect can be achieved by delivering a similar total energy over a shorter period of time.

- Riboflavin e/d for 15 mins followed by 3 mins of UVA (30 mW/cm^2)

Newer advances in C3R

Pulse C3R - In accelerated C3R, pulsed radiation is delivered to allow oxygen diffuse into stroma.

Epi-on C3R - Corneal enhancing compounds like BAK, EDTA and tetracaine can improve riboflavin diffusion despite epithelial presence

C3R using topography guided UVA radiation.

Surgical management

Indications :-

- Excessive corneal thinning
- Scarring of cornea.

- Penetrating keratoplasty - gold standard Sx
  - 90% success rate.

- DALK - Deep anterior lamellar keratoplasty.

Stroma is transplanted and patient's corneal endothelium is retained. Chance of rejection is greatly reduced.

Differential diagnosis :-

1. Pellucid marginal degeneration

Non-inflammatory thinning of peripheral cornea between 4-8 o clock positions.

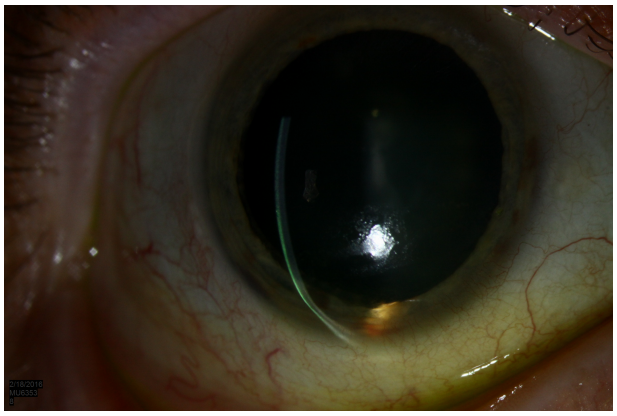

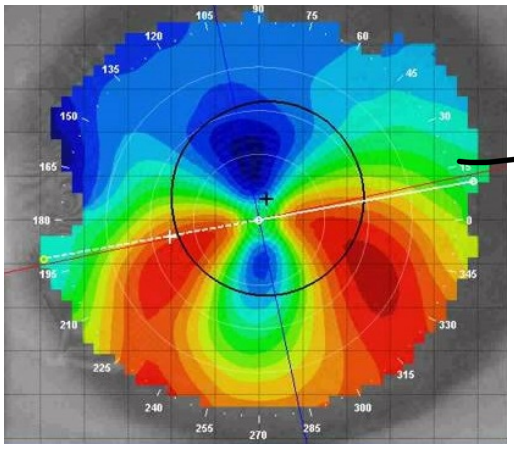

lobster claw appearance

2. Terrien marginal degeneration :-

Slowly progressive thinning of peripheral cornea with deposition of refractile yellow white dots in peripheral anterior stroma.

Thinning starts in superior region and extends 360°.

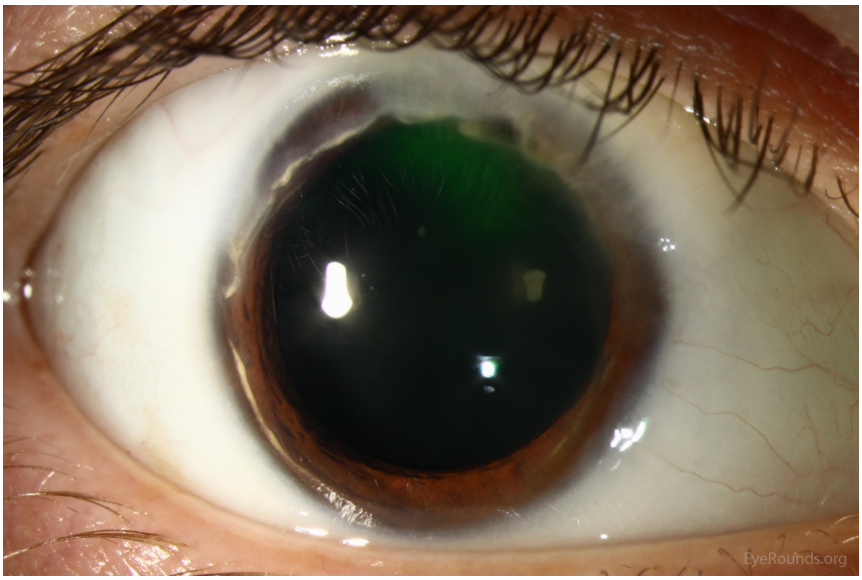

3. Keratoglobus :-
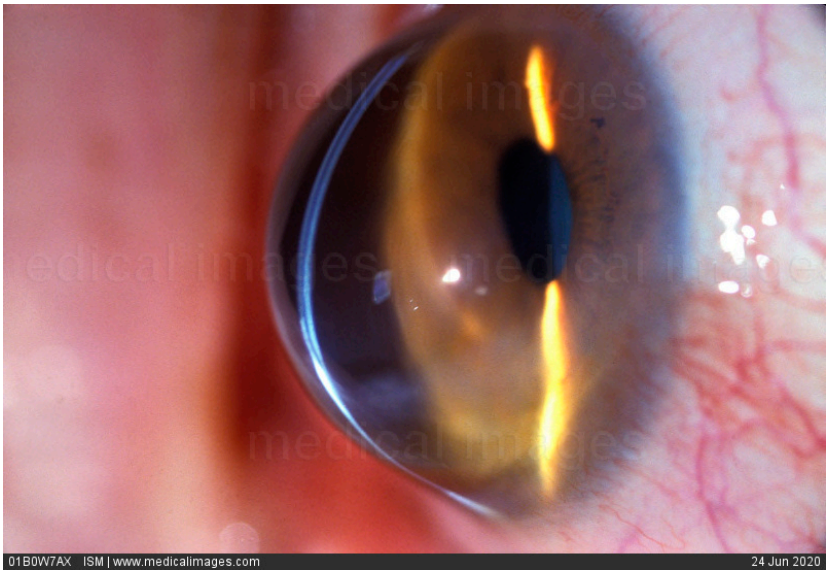
Corneal thinning at margins resulting in a spherical and slightly enlarged eye.